



VeraLook



VeraLook CAD for CTC Increases Radiologists' Abilities to Detect Polyps

Abraham H, Dachman, MD

The use of Computed Tomographic Colonography (CTC), also known as Virtual Colonoscopy, has increased in recent years as numerous large multi-center clinical trials performed in both academic and community settings have shown sensitivity and specificity very comparable to that of traditional colonoscopy. American College of Radiology Imaging Network (ACRIN) released results of its multicenter National CTC Trial on September 18, 2008 where CTC screening identified 90% of asymptomatic patients with cancers or polyps ≥ 10 mm in diameter.¹

On March 5, 2008, the American Cancer Society, the U.S. Multi-Society Task Force on Colorectal Cancer, and the American College of Radiology issued new cancer screening guidelines recommending CTC be an option for colorectal cancer screening.² CTC is also recommended for patients with failed optical colonoscopies due to a variety of reasons or where optical colonoscopy is contraindicated due to complications with anesthesia. In 2010, the FDA cleared the first Computer Aided Detection (CAD) software for CTC, VeraLook®. VeraLook has been shown to result in a significant improvement in overall reader performance, both for experienced and inexperienced readers.³

Dr. Abraham Dachman, Professor of Radiology at the University of Chicago Medical Center, has been interpreting CTC studies since 1997. He uses the VeraLook CTC CAD solution when reading all CTC studies to improve the detection of polyps and make his reading workflow more efficient. The case below demonstrates how CAD supported the detection of significant polyps that would have been missed during a routine screening of a patient with numerous polyp candidates. VeraLook CAD highlighted an 11mm polyp, allowing the radiologist to assess its clinical significance.

History

64 year old male with CHF being worked up for cardiac transplant. No prior colorectal cancer screening. No GI signs or symptoms. Due to the risk of anesthesia and the risk of stopping the patient's anticoagulant therapy, all cardiac transplant candidates are screened with virtual colonoscopy.

Patient Preparation

The patient underwent a one-day prep with a liquid diet, afternoon 2 liter cathartic with polyethylene glycol (HalfLytle™). 60 cc iohexol (Omnipaque™) was given in divided doses in the evening prior to the exam after completing the cathartic and on the morning of the exam.

Virtual Colonoscopy Technique

Colonic insufflation was performed with CO₂ using a mechanical insufflator (ProtoCO₂L®, Bracco Diagnostics, Inc.) to patient tolerance. The patient was scanned supine and prone on a Philips 256 Brilliance iCT scanner, 30 mAs, kVp 120, (CTDIvol 1.91 mGy/series) 128 x 0.625, 1.25 mm slice thickness, 0.75 mm increments.

Interpretation

The exam was interpreted on a Viatronix V3D™ Colon Workstation using iCAD VeraLook CTC CAD v1.0 with a primary 3D read with 2D problem solving.

Findings

The patient preparation and the colonic distention were excellent. The interpretation was difficult due to numerous polyp candidates. Some polyps were missed by the radiologist at the initial read. The largest most important polyp was an 11mm polyp in the sigmoid colon.

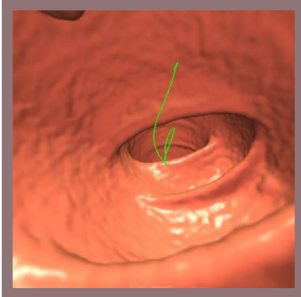


Figure 1. Supine 3D fly-through at 120° fly-through showing the polyp, barely visible in the upper right corner of the field of view.

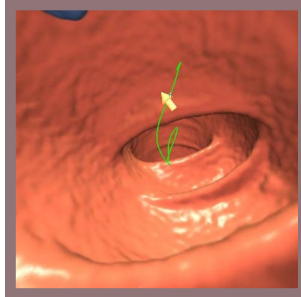


Figure 2. With VeraLook CAD turned on, attention is quickly drawn to the polyp, even before checking the CAD hit list.

This polyp was seen at the edge of the 120° fly-through field in several views (**figure 1**), but attention was quickly drawn to it with VeraLook CAD turned on (**figure 2**).

After problem solving, the confirmed CAD hit can be seen in optimized 3D viewing angles on the supine and prone views with corresponding 2D views (**figure 3**):

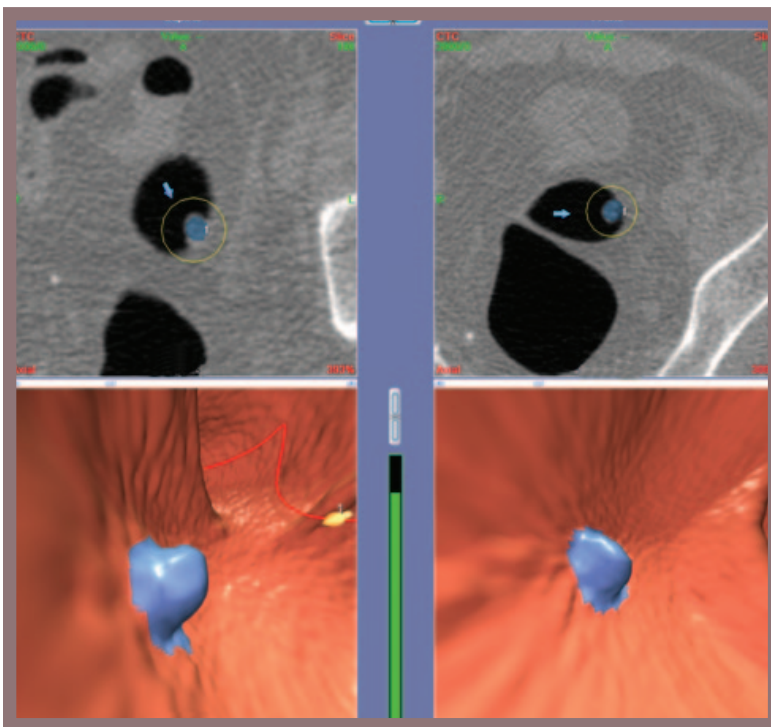


Figure 3. Combined supine and prone views. The 3D viewing angle (bottom row) was adjusted to find the polyp shown with the corresponding 2D views (top row) with the VeraLook CAD turned on which colors the polyp blue.

¹ Johnson CD, et al. "Accuracy of CT colonography for detection of large adenomas and cancers." *N Engl J Med* 2008; 359:1207-17.

² Levin B, et al. "Screening and Surveillance for the Early Detection of Colorectal Cancer and Adenomatous Polyps, 2008: A Joint Guideline from the American Cancer Society, the US Multi-Society Task Force on Colorectal Cancer, and the American College of Radiology", *CA Cancer J Clin* 2008; 58:130-160.



98 Spit Brook Road, Suite 100 Nashua, NH 03062

+1 866 280 2239 toll free +1 937 431 1464 phone sales@icadmed.com email

www.icadmed.com