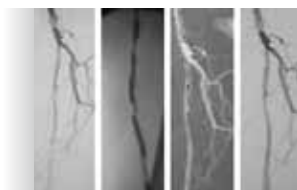




DIAGNOSTIC IMAGING EUROPE

PERIPHERAL ARTERY DISEASE



Perspectives on the management of Peripheral Artery Disease (PAD) in a globally renowned leading institution, the University Hospital of Leipzig, Germany

Breast Imaging Special

- Breast Imaging News
- More cancers detected with combination of mammography and tomosynthesis.
- Breast imaging in a dynamic private radiology practice in the west of Germany
- Combined Automated Breast Ultrasound and Digital Breast Tomosynthesis imaging
- Can we make breast tomosynthesis feasible for screening?
- Ultrasound and MRI in the evaluation of mammographic BI-RADS 4 and 5 micro-calcifications
- ABUS Designed for Large Scale Population Screening
- The use of citizens' juries in decision-making processes in screening mammography

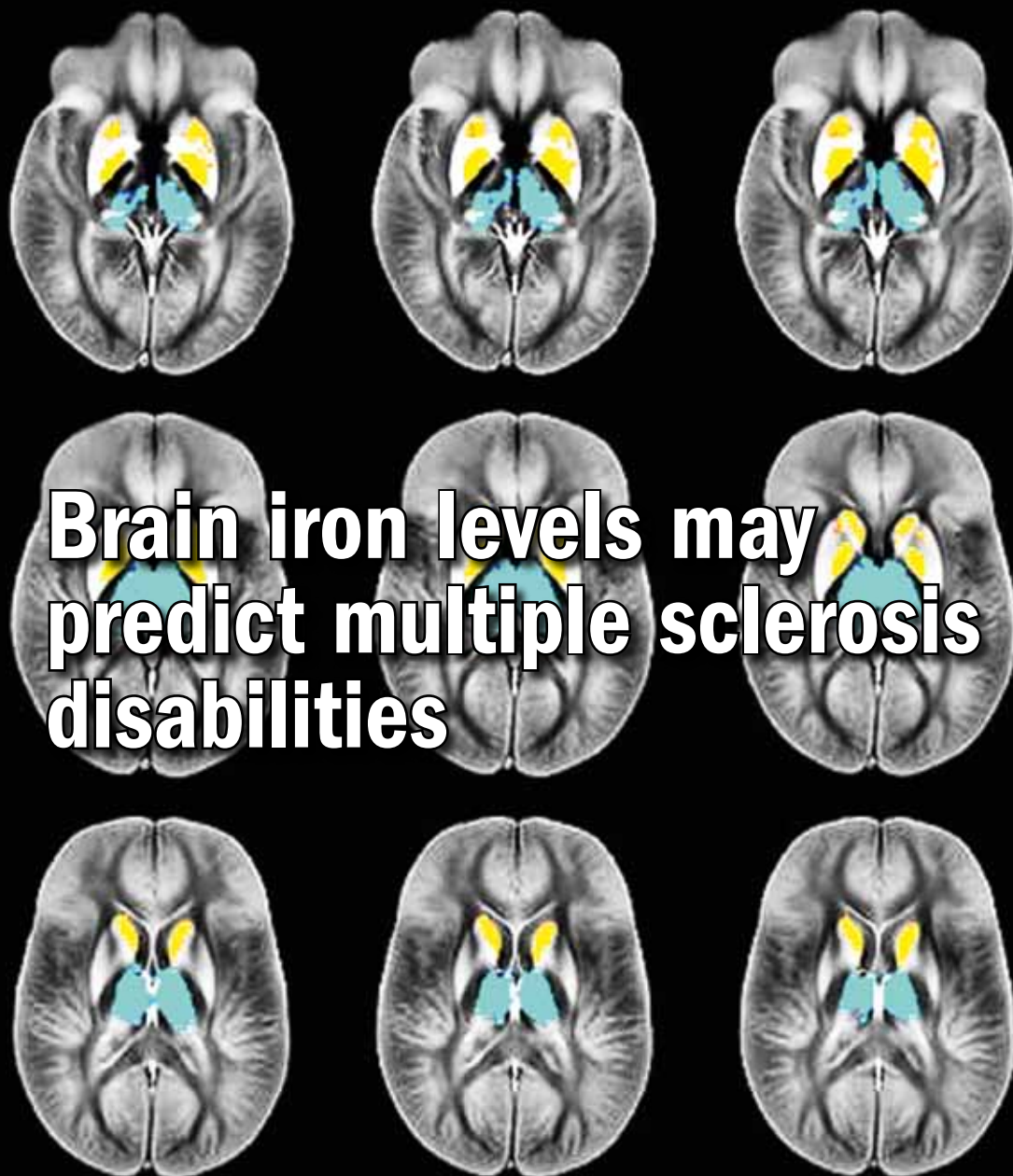
Feature articles

- One-year OCT findings in patients with late and very-late stent thrombosis treated with IVUS-guided PCI
- Making MRI Faster, Smarter, Simpler
- Reproducibility and redundancy in radiomic CT features

Imaging News

Industry News

Technology Update



Brain iron levels may predict multiple sclerosis disabilities

Breast imaging in a dynamic private radiology practice in the west of Germany

Ever since its creation nearly 60 years ago, the private radiology practice “Radiologie am Theater” situated in the city of Paderborn in the west of Germany, has always adopted a policy of employing state-of-the-art equipment and highly trained, experienced radiologists to provide a high quality and reliable service for patients and referring physicians. True to this philosophy of using the latest technology wherever it can provide clinical benefits, the practice has recently acquired a new artificial intelligent (AI), deep learning software system to aid in the reading of digital breast tomosynthesis (DBT) images.

We wanted to find out more about the practice in general and the center’s experience with the new artificial intelligent system from iCAD, so we spoke to Dr Axel Gräwingholt, head of the department of mammography screening.



Dr Axel Gräwingholt is head of the department of mammography screening in the “Radiologie am Theater” practice in Paderborn, Germany. Dr Gräwingholt is currently co-chair of the ECIBC’s Guidelines Development Group
E-mail: axel.graewingholt@t-online.de

Q *Before focusing on the breast imaging and screening activities, please give us a brief introduction to the “Radiologie am Theater” center as a whole and your own professional background?*

In fact, our practice involves three separate sites. The biggest is the “Radiologie am Theater” — so-called since it is located very close to the city theater in downtown Paderborn, but we also have another two locations, one in the St. Johannisstift hospital, also in the town center of Paderborn and yet another in the nearby town of Bad Lippspringe. Between these sites, we offer all principal imaging modalities, including MRI, CT, ultrasound, X-ray and bone densitometry.

As for me, my main interest is in breast imaging. I have been working in breast cancer detection for 25 years now.

Thus, ever since 2006, when the German National Breast Screening Program started, we set up a breast screening unit in Paderborn. I have also been involved as a consultant in several regional screening programs in Switzerland and as a supervising

reader also for the assurance of imaging quality. Since 2015, I have been a member of the Guidelines Development Group of the European Commission Initiative on Breast Cancer (ECIBC). This is a European Union sponsored initiative whose aim is the development of the most up-to-date evidence recommendations on screening and diagnosis and the creation of a platform of reliable guidelines covering the whole breast cancer care pathway. Since 2017, I have been the clinical co-chair of ECIBC’s Guidelines Development Group. But, to come back to our activities at Paderborn, we carry out a total of 15000 breast exams every year.

Q *Of these exams, how many are diagnostic and how many are screening mammography?*

The breakdown of the 15,000 breast exams we carry out each year is approximately one third diagnostic mammography and two-thirds screening. The women referred to us come predominantly from the area around Paderborn and further afield from across the North-Rhine

Westphalia state and are largely representative of the indigenous population, thus with a typical average Caucasian breast density profile.

In Germany, as in most European countries, screening is carried out using 2D mammography, whereas diagnostic examinations can, at the discretion of the radiologist, be carried out using digital breast tomosynthesis (DBT). For screening mammography, double reading is mandatory. For DBT, officially double reading is not mandatory; nevertheless, we systematically carry out double reading for all our mammography and tomosynthesis exams.

Any suspicious soft tissue lesions detected after double reading in screening will result in a recall of the woman concerned. In this recall examination, a final assessment is usually made by tomosynthesis. If necessary, an ultrasound examination will also be carried out and then eventually an ultrasound-guided biopsy may be taken. For microcalcifications, a typical work-up would involve magnified views, ultrasound and stereotactic-guided biopsy when indicated.

Fortunately, we are well-equipped to carry out all these examinations: we have three GE Senographe Essential tomosynthesis systems, one of which also has the capability of performing Contrast-Enhanced Spectral Mammography (CESM). Our ultrasound systems are also from GE, as is our MRI.

Q So what is the current role that tomosynthesis has in your practice?

Currently we use DBT principally for diagnostic imaging and in definitive assessment of cases coming from screening, but we are also evaluating its role in primary screening. Overall, I believe that DBT has the potential to become increasingly important in both breast cancer diagnosis and screening and could eventually replace mammography altogether. This belief is based on the results of several trials which have shown that the cancer detection rates using tomosynthesis are significantly higher than those with 2D digital mammography, especially for invasive cancers. This is important since excessive increases in the detection of non-invasive cancers, such as ductal carcinoma in situ (DCIS) have been associated with overdiagnosis and consequent overtreatment.

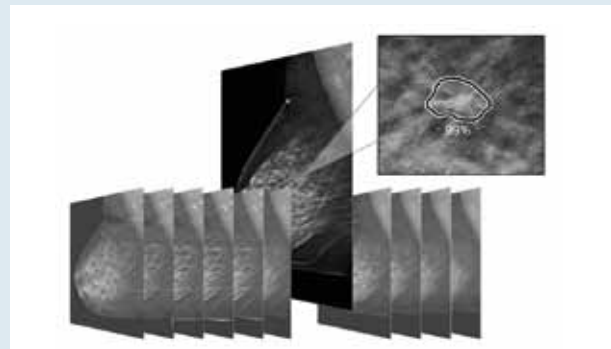
There are several trials currently ongoing to determine how, in practice, tomosynthesis could or should be implemented in routine screening programs.

Depending on the results of these trials, the precise role of tomosynthesis in breast imaging will be addressed and if necessary incorporated into the appropriate EU-guidelines.

However, with all the advantages of DBT in terms of higher detection rates, let's not forget that DBT still has some drawbacks. For example, there have been some questions about the ability of DBT to reliably detect microcalcifications (although recent findings suggest that this may not be such a big problem after all); DBT could also involve the use of a higher level of ionizing radiation, especially if in addition there is a need to acquire a 2D mammogram to compare with prior images. In practice, however, the quality of the synthetic 2D mammogram created by software from the data contained in the tomo slices is such that it avoids the necessity of a separate 2D acquisition. Thus, in our hands, DBT involves the same level of radiation as 2D mammography. DBT also inevitably generates a huge amount of data which has to be handled and stored appropriately. However, from the work-flow point of view, perhaps the most significant drawback of DBT is that not only the examination itself take slightly longer than a standard 2D mammogram but also, the reading time is much longer since the breast radiologist must read each of several sliced images of the breast. The fact that DBT requires more radiologist reading time is all the more acute given the ever-increasing work-load of radiologists and the current shortage of available radiologists.

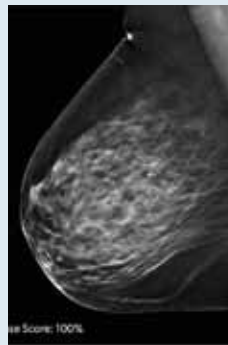
Thus, there is pressing need to find a product that could help with this drawback; this is why I first became interested in the Tomo Detection 2.0 AI Deep Learning system from iCAD.

Artificial Intelligence for Digital Breast Tomosynthesis (DBT) iCAD's PowerLook Tomo Detection 2.0



Lesion Score. Each tomosynthesis plane is analyzed and detections are assigned a Lesion Score on a scale from 0 - 100%. This score represents the algorithm's level of confidence that the lesion is malignant.

DBT is one of the most accurate screening methods available for detecting breast cancer. However, the method produces significantly more images than full-field digital mammography (FFDM) therefore, DBT requires considerably more time for radiologists to review. Thus, a major advancement in DBT would be to shorten radiologist reading time, while maintaining high clinical performance. Built on artificial intelligence and deep learning, PowerLook Tomo Detection 2.0 rapidly analyzes each tomosynthesis image, detecting malignant soft tissue densities and calcifications.



Case Score. Each tomosynthesis case is analyzed and assigned a Case Score on a scale from 0 - 100%. The Case Score represents the algorithm's confidence a malignancy is present. The Case Score can also be used to assist radiologists in the prioritization of their caseloads.

The system is compatible with GE, Hologic and Siemens digital breast tomosynthesis and will soon be compatible with other vendors. Tomo Detection 2.0 provides unprecedented algorithm performance in sensitivity and specificity, with a high malignant detection rate and a high percentage of normal cases with no detections. In addition, each case and each detected lesion is assigned a "Certainty of Finding" score that refers to the algorithm's confidence that there is a malignancy. The algorithm is built on thousands of cases both with benign lesions and biopsy-proven malignancies. Represented as a score of 0-100 percent, a higher score indicates a higher confidence of a malignant finding. In a recent reader study, Tomo Detection 2.0 was shown to improve radiologist workflow by reducing the reading time by 52.7%. Moreover, in this study, Tomo Detection 2.0 helped radiologists improve their sensitivity by an average of 8% and improve their specificity by an average of almost 7%. Tomo Detection 2.0 can help radiologists read tomosynthesis exams faster and with more precision.

BREAST IMAGING

Q *Why exactly did you choose this system?*

First of all, iCAD is a well-known company that has had Computer Aided Detection products on the market for many years and is an established leader in solutions for breast imaging. Of course, before opting for the iCAD product I evaluated competitors' products, but in the end, I considered that the improvement in sensitivity and in workflow could best be attained with iCAD's AI Deep Learning cancer detection product. The system seemed intuitive and easy to use and, in practice, after installation, it turned out that product training was short, efficient and very easy to understand even for inexperienced users. Our learning curve was very rapid.

Q *What in particular makes you feel confident about using iCAD's AI Deep Learning product in real clinical use?*

Of course, we have to be absolutely sure about all the systems we use for our patients. In short, our confidence in the system is based on reader study results and our own current experience.

Studies have shown that by using the system, the average reader can benefit from an average increase in sensitivity of 8.0% or in specificity of 6.9% or in both at the same time! Additionally, while the default operational mid-point performs on average at 91% sensitivity and 60% specificity, the radiologist can change this setting to meet his or her own personal preferences or examination needs.

I have now personally reviewed retrospectively many cases from our screening program where the lesions have been biopsied, and their characteristics verified by pathology. The objective of this exercise was to evaluate the performance of the new iCAD AI system with various subgroups of confirmed cancers and to compare the findings with those of the radiology readers working in our screening program. To put it simply, the findings are (perhaps not surprisingly), that the effectiveness of this product in detecting lesions is always constant. The product points out significant lesions, including many that might have been missed by the radiologist, for example at the end of a busy day with frequent interruptions. The radiologists appreciate the system in that it acts as a back-up for their own performance. The retrospective studies with relatively

limited patient numbers that we used to evaluate the system are of course only anecdotal evidence, but nevertheless show the potential of this AI product and future applications.

Q *In practice what impact do you foresee the Tomo Detection 2.0 having on your workflow?*

Based on our experience so far, I foresee a very positive impact on our workflow. In an ideal world, someday, hopefully in the near future, we will be able to use tomosynthesis in screening and, through



The Breast Imaging section of the "Radiologie am Theater" center is well-equipped, with three GE Senographe Essential tomosynthesis systems.

the use of this product, even be able to read as many tomosynthesis cases as we currently read with 2D mammography and with more confidence in the results. If AI can systematically and reliably identify "true negatives", I will be freed up to spend more time on trickier tomosynthesis images with perhaps ill-defined but suspicious lesions. By providing probabilities (percentage scores) based on the algorithm's certainty of finding for lesions and the entire tomosynthesis case, this system will enable me to focus my reading time on cases which really need close attention. This helps to keep the work focused.

One large study has already shown that iCAD's AI product can reduce tomosynthesis reading time by 52.7%.

From the patient's point of view, they expect to experience the least amount of stress and the shortest waiting time for results as possible. From the center's point of view, I naturally want to see our patients in an as efficient and rapid way as possible; therefore, faster reading time allows us to see more patients. The processing time of this tool is only 1-2 minutes per case, so

"... the new Tomo Detection 2.0 system can reduce tomosynthesis reading time by almost 53% ..."

I am able to give the patients undergoing diagnostic imaging their accurate, reliable results right away. This advantage is currently not directly applicable to screening, since our double reading system only starts after the woman has left the unit.

Q *What are the biggest benefits you've seen since you've implemented this AI tool?*

Out of curiosity, I had a look at a diagnostic tomosynthesis case just a few days ago where the product detected a suspicious lesion. We carried out an ultrasound exam right away and it showed a benign lesion in the breast. Normally we carry out second readings on all diagnostic mammograms; if the second reader detects something that the first reader had missed, we would recall the woman or the referring physician to carry out the additional exams. This inevitably leads to a lot of anxiety for the woman but could be avoided if Tomo Detection was used routinely in diagnostic tomosynthesis. This way we would be able to immediately react and if a lesion is detected, we could carry out any necessary interventions right away.

Of course, we must keep in mind that AI systems can't do miracles. Cancers that, because of their appearance and characteristics, are hard to detect by human readers are also harder for algorithms to detect.

Q *As we move into a future of screening with tomosynthesis, what advice would you give any radiologists who might be thinking of implementing tomosynthesis in their clinic?*

That's easy to answer — make sure you have help from AI products such as iCAD's. It's not only important to be a center where cancer is reliably detected but, from the efficiency point of view, it is also important that the otherwise long reading times involved with breast tomosynthesis are reduced.

AI can then free the radiologist up to focus on more difficult cases, so overall helping to minimize misdiagnoses or mismanagement.